

## **SINGLE INCISION LAPAROSCOPIC CHOLECYSTECTOMY – COMPARAISON OF TWO DIFFERENT TECHNIQUES**

**Iova Camelia\*, Maghiar Adrian\*\*, Dejeu George\*\***

\*Bihor County Public Health Authority, 34 Libertății St., Oradea, Romania, e-mail:  
[camyowa@yahoo.com](mailto:camyowa@yahoo.com)

\*\*University of Oradea, Faculty of Medicine and Pharmacy, Oradea, 1 December Street,  
nr.10, Romania

### **Abstract**

*Laparoscopic cholecystectomy remains the gold standard for gallbladder removal, but this procedure tends to become more and more developed, in intent to reduce the scars and patient's sufferance. The ultimate goal is to achieve "scarless" surgery, by permanent reduction in the size and number of ports.*

*The aim of this study was to determine the differences between the two surgical techniques used to perform single incision laparoscopic cholecystectomy, in terms of patient's characteristics, preoperative, operative and postoperative parameters.*

**Key words:** SILC, pupeteer, Dapri-Storz forceps.

### **INTRODUCTION**

Single incision laparoscopic surgery was first described in the field of gynecology, by Wheeless, in 1969, when he reported tubal ligation performed with this technique (Wheeless CR, 1969). In 1992, Pelosi and his colleagues reported the first single incision laparoscopic appendectomy (Pelosi MA, MA Pelosi 3rd, 1992). The transumbilical approach for gallbladder removal was first reported by Navarra in 1997 (Navarra G. et al, 1997). Since then, the procedure had evolved continuously by further development of laparoscopic equipments and introduction of curved and articulated instruments (Bhandarkar D et al, 2011, Cuesta MA et al, 2008, Curcillo PG et al, 2010, Rao PP, PP Rao, S. Bhagwat, 2011).

### **MATERIAL AND METHOD**

This study included 100 patients admitted in the surgery department of Pelican Hospital Oradea during september 2009 and december 2013. In all of these patients, single incision laparoscopic cholecystectomy was performed by using two different approaches. One of the approaches

involved the puppet of the gallbladder by using transcutaneous sutures (the puppeteer technique) and the other the use of the Dapri forceps (Dapri technique).

The puppeteer technique: an umbilical incision of 2 cm is made, followed by the introduction of the first 10 mm trocar (the optic one) and laparoscopic thorough inspection, in order to exclude extensive omental or intestinal adhesions. A second trocar, also of 10 mm, is placed lateral to the first one, used to handle the dissector, the hook cautery, the scissors, the needle holder and the clip applicator. After the trocar's introduction, three transparietal sutures are placed and tension is applied in different degrees, in order to puppet the gallbladder and expose the Calot triangle.

The Dapri technique was introduced in the practice of the surgery department in January 2011 and involves the use of the double curved Dapri-Stroz forceps, thus eliminating the need for the transparietal sutures on the sides.

Data taken into consideration were preoperative parameters (the environment, gender, age, body mass index and American Society of Anesthesiologists classification), peroperative parameters (operating time, need for an extra trocar, conversion to standard laparoscopic cholecystectomy) and postoperative parameters (duration of hospitalization, complications, readministration to the hospital and mortality).

## RESULTS AND DISSCUSIONS

In 2009 and 2010, the intervention was performed with the puppeteer technique and from January 2011, the Dapri curved forceps was introduced in order to complete SILS cholecystectomy. Therefore, the puppeteer method was used in 56 patients (56%) and the Dapri method in 44 patients (44%). (fig. 1)




Fig. 1. The distribution of the cases according to the technique

In the puppeteer group, 41.07% of the cases were from urban areas and 58.93% of the cases were from rural areas; in the Dapri group, 56.82% of the patients came from urban areas and 43.18% from rural areas. (fig. 2)



Fig. 2. The distribution of the cases according to the environment

The majority of the patients in both groups were females (87.50% in the puppeteer group, respectively 77.27% in the Dapri group). (fig. 3)



Fig. 3. The distribution of the cases according to the gender

Most of the cases in the puppeteer group (26.78%) were in the age group of 30 - 39 years and most of those from the Dapri group (25%) were aged between 20 and 29 years. (fig. 4)

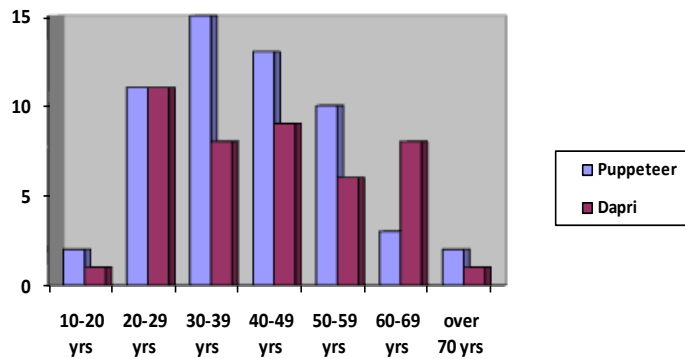


Fig. 4. The distribution of the cases according to the age

Grade I obesity was present in 23.21% of the patients in the puppeteer group, respectively in 13.63% of the cases in the Dapri group, grade II obesity in 7.14%, respectively no cases in the Dapri group and morbid obesity in 2.27% of the cases in the Dapri group and no cases in the puppeteer group. (table 1)

Table 1

The distribution of the cases according to the BMI

Body mass index (kg/m <sup>2</sup> )	Puppeteer group (nr./%)	Dapri group (nr./%)
<b>&lt;=18.49</b>	1/1.78	-
<b>18.5-24.99</b>	19/33.93	18/40.90
<b>25-29.99</b>	19/33.93	19/43.18
<b>30-34.99</b>	13/23.21	6/13.63
<b>35-39.99</b>	4/7.14	-
<b>&gt;=40</b>	-	1/2.27

According to the American Society of Anesthesiologists classification, most of the patients in both groups (98.21%, respectively 95.45%) belonged to ASA I and ASA II class. (fig 5)




Fig. 5. The distribution of the cases according to the ASA classification

The mean operative time was 49.55 minutes for the puppeteer technique and 41.58 minutes for the technique using the Dapri curved forceps. Conversion to the standard laparoscopic cholecystectomy was necessary in 3 cases and an extra port was needed in 2 cases. (table 2)

Table 2

Peroperative parameters

	<b>Puppeteer group</b>	<b>Dapri group</b>
<b>Mean operative time (min)</b>	<b>49.55</b>	<b>41.58</b>
<b>Conversion</b>	<b>3</b>	<b>-</b>
<b>Need for extra trocar</b>	<b>-</b>	<b>2</b>

Mean hospitalization time was 3.10 days in the puppeteer group and 3.65 days in the Dapri group. There were no complication and no deaths in any group. (table 3)

Table 3

Postoperative parameters

	<b>Pupeteer group</b>	<b>Dapri group</b>
<b>Mean hospitalization time (days)</b>	<b>3.10</b>	<b>3.65</b>
<b>Complications</b>	<b>-</b>	<b>-</b>
<b>Readmission</b>	<b>-</b>	<b>-</b>
<b>Mortality</b>	<b>-</b>	<b>-</b>

## CONCLUSIONS

Single incision laparoscopic surgery is a safe, feasible and, without doubt, a cosmetically advantageous procedure that can be performed by using different techniques (Rao PP, SM. Bhagwat, A. Rane, 2008, Rivas H, E. Varela, D.Scott, 2010, Romanelli JR et al, 2010, Shaikh HR, M. Mahesri, A. Abbas, 2011, Zheng M, M. Qin, H. Zhao, 2012, Shussman N et al, 2011). The puppeteer technique is less expensive and does not require special instruments, but the introduction of curved instruments represents a real advantage in terms of surgeon ergonomics. More studies are needed to compare the outcomes of both procedures, in order to decide the advantages of one technique over the other.

## REFERENCES

1. Bhandarkar D, G. Mittal, R.Shah, A. Katara, TE. Udwardia, 2011, Single-incision laparoscopic cholecystectomy: How I do it? *J Minim Access Surg.* Jan-Mar; 7(1): 17–23
2. Cuesta MA, F. Berends, AA.Veenhof , 2008 , The “invisible cholecystectomy”: a transumbilical laparoscopic operation without a scar. *Surg Endosc* 22:1211–1213
3. Curcillo PG, AS. Wu, ER. Podolsky, C. Graybeal, N. Katkhouda, A.Saenz et al, 2010, Single-port-access (SPA) cholecystectomy: A multi-institutional report of the first 297 cases. *Surg Endosc*;24:1854–60
4. Navarra G, E.Pozza, S. Occhionorelli, P.Carcoforo, I.Donini, 1997, One-wound laparoscopic cholecystectomy. *Br J Surg.*; 84:695
5. Pelosi MA, MA Pelosi 3rd, 1992, Laparoscopic appendectomy using a single umbilical puncture (minilaparoscopy). *J Reprod Med.* ;37(7):588–94
6. Rao PP, PP Rao, S. Bhagwat, 2011, Single-incision laparoscopic surgery - current status and controversies. *J Minim Access Surg.*; Jan-Mar; 7(1): 6–16
7. Rao PP, SM. Bhagwat, A. Rane, 2008, The feasibility of single port laparoscopic cholecystectomy: A pilot study of 20 cases. *HPB (Oxford)* ;10:336–40
8. Rivas H, E. Varela, D.Scott, 2010, Single-incision laparoscopic cholecystectomy: initial evaluation of a large series of patients.*Surg Endosc* 24(6):1403–1412
9. Romanelli JR, TB III Roshek, DC. Lynn, DB.Earle, 2010, Single-port laparoscopic cholecystectomy: initial experience. *Surg Endosc.* 24(6):1374–1379
10. Shaikh HR, M. Mahesri, A. Abbas, 2011, Single incision laparoscopic cholecystectomy: overcoming the learning curve.*Surg Endosc.*; 25: S337
11. Shussman N, A. Schlager, R. Elazary, A. Khalaileh, A. Keidar, M. Talamini, S. Horgan, Al. Rivkind, Y. Mintzet, 2011, Single-incision laparoscopic cholecystectomy: lessons learned for success. *Surg Endosc* 25:404–407
12. Tacchino R, F. Greco, D.Matera, 2009, Single-incision laparoscopic cholecystectomy: surgery without a visible scar. *Surg Endosc*; 23: 896-899
13. Wheelless CR, 1969, A rapid, inexpensive and effective method of surgical sterilization by laparoscopy. *J Reprod Med.* ;3(5):65–9
14. Zheng M, M. Qin, H. Zhao, 2012, Laparoendoscopic single-site cholecystectomy: a randomized controlled study. *Minim Invasive Ther Allied Technol*; 21: 113-117
15. Zhu JF, 2007, Scarless endoscopic surgery: NOTES or TUES .*Surg Endosc* 21:1898–1899